

Canadian J Research

Section E 37: 105-119, 49

105

ACETYLCHOLINE AND NEURONAL ACTIVITY

I. CHOLINESTERASE PATTERNS AND ACETYLCHOLINE IN THE CEREBROSPINAL FLUIDS OF PATIENTS WITH CRANIOCEREBRAL TRAUMA¹

BY DONALD B. TOWER AND DONALD MCEACHERN

Abstract

Cerebrospinal fluid acetylcholine and cholinesterase determinations were made on 112 neurological and neurosurgical patients. Results on 15 patients with craniocerebral trauma and six psychiatric patients treated with electric shock convulsant therapy (E.C.T.) are reported in detail. Except for epileptics the only cerebrospinal fluid assays positive for acetylcholine occurred in the traumatic and E.C.T. groups, in which acetylcholine levels were 0.2 to 100+ $\mu\text{gm. } \%$. In contrast to all other patients cerebrospinal fluid cholinesterases of traumatic and E.C.T. groups showed reversals of normal fraction patterns. These consisted of reduction of specific and increase of unspecified cholinesterase fractions, together with decrease of total cholinesterase activity. Acetylcholine levels and extent of cholinesterase fraction reversals paralleled the severity of cerebral damage, judged by clinical and electroencephalographic (E.E.G.) signs. Coma or semiconsciousness and depression of E.E.G. activity were associated with presence of acetylcholine and marked reversals of cholinesterase fractions in cerebrospinal fluids. In less severe cases and during recovery, when patients were disoriented and confused and E.E.G. activity was increased, cerebrospinal fluid acetylcholine decreased and disappeared, and cholinesterase values returned toward normal. Similar cerebrospinal fluid abnormalities were seen in patients after E.C.T. Changes in cerebrospinal fluid cholinesterase fraction patterns seem to be sensitive indications of extent of cerebral injury and progress toward recovery.

Introduction

In the course of studies on acetylcholine and cholinesterases in cerebrospinal fluids from 112 neurological and neurosurgical patients, interesting findings were obtained in the group with craniocerebral trauma. The literature on experimental studies of the physiology of craniocerebral trauma has been reviewed by Bornstein (3). He carried out animal experiments to investigate the role of acetylcholine in the post-traumatic state. He felt that there was a relationship of post-traumatic behavior, electroencephalographic abnormalities, and cerebrospinal fluid acetylcholine levels with the severity of concussion. He was able to reproduce these changes in unanesthetized animals by perfusion of the cortex with acetylcholine in concentrations of 1.0 to 10.0 $\mu\text{gm. } \%$. With concentrations below 2.0 $\mu\text{gm. } \%$, Bornstein (3) observed excitatory or synchronizing effects of acetylcholine on behavior and on the electroencephalograms (E.E.G.), while depressant effects appeared at higher concentrations.

We have reported in other papers the content and types of cholinesterases to be found in human cerebrospinal fluids (22) and the acetylcholine levels found in the same cerebrospinal fluid samples (8, 23). Three groups of

¹ Manuscript received December 2, 1948.

Contribution from the Department of Neurology and Neurosurgery, McGill University, and the Montreal Neurological Institute, Montreal, Canada.

This study was supported by a grant from the Rockefeller Foundation and was presented in part at the annual meeting of the American Society for Clinical Investigation, Atlantic City, N.J., May 3, 1948.

E.C.T. -
PINK

PINK
1966

patients have been recognized. (a) Normal individuals and patients with various neurological disorders: In this group cerebrospinal fluid cholinesterase values were normal and acetylcholine was absent from the cerebrospinal fluid. (b) Epileptic patients: In this group cerebrospinal fluid cholinesterase values were normal and acetylcholine was present in the cerebrospinal fluids (in amounts from 0.02 to 5.0 $\mu\text{gm. } \%$). (c) Craniocerebral trauma patients and patients treated with electric shock convulsant therapy (E.C.T.): In this group cerebrospinal fluid cholinesterase values were abnormal and acetylcholine was present in the cerebrospinal fluids in most instances. Clinical and E.E.G. observations of the traumatic group indicated that we were seeing for the first time in human patients phenomena that Bornstein (3, 4) had described in experimental animals.* No cerebrospinal fluid cholinesterase determinations were made by Bornstein (3, 4), so that abnormalities in the enzyme values reported here are the first to demonstrate their association with craniocerebral trauma.

Materials and Methods

Cerebrospinal fluid samples from 112 neurological and neurosurgical patients were examined for acetylcholine levels, cholinesterase values, and routine constituents. Of the samples, 80% were obtained during pneumoencephalography, the remainder during ventriculography (4%) or lumbar puncture (16%). Cell counts, Pandy tests, and protein determinations were carried out on all samples. Cerebrospinal fluid cholinesterase activities and fraction characterizations (using acetylcholine (ACh), mecholyl (MeCh), and benzoylcholine (BCh) as substrates) were done by our modification (22) of the Warburg method of Ammon (1a), Odom *et al.* (18) and Nachmansohn and Rothenberg (17). Cerebrospinal fluid samples for acetylcholine analysis were preserved by a modification (20) of the method of Babkin *et al.* (2) and later assayed by our modification of the method of Wait (24) on the isolated ventricle of *Venus mercenaria* (21). Electroencephalograms (E.E.G.) were taken by conventional four-channel ink-writing recorders through the cooperation of the Department of Electroencephalography.

Results

1. Cerebrospinal Fluid Acetylcholine and Cholinesterases

Of the 112 patients studied 15 were cases of craniocerebral trauma and nine, cases treated by electric shock convulsant therapy (E.C.T.). Only these 24 cases are considered at length in this paper. The clinical diagnoses of these patients are included in Tables III and IV.

A total of 59 cerebrospinal fluid samples from 53 nonepileptic patients were assayed for acetylcholine.** The results are summarized in Table I.

* The inclusion of patients treated by electric shock convulsant therapy (E.C.T.) with cases of craniocerebral trauma may seem surprising. We feel that the application of convulsive electric shocks to the cortex may be closely allied pathologically to a blow on the head (see Discussion).

** The results of acetylcholine assays on 60 cerebrospinal fluid samples from 57 epileptic patients are reported in a separate paper (8, 23).

TABLE I

CEREBROSPINAL FLUID ACETYLCHOLINE ASSAYS IN 53 NONEPILEPTIC PATIENTS

Sample type	ACh positive	ACh negative	Total
Craniocerebral trauma patients	7 (35 %)	13 (65 %)	20
E.C.T. treated psychiatric patients	2 (33 %)	4 (67 %)	6*
Untreated psychiatric patients	0	4 (100 %)	4*
Others	2 (7 %)	28 (93 %)	30
	—	—	—
Total	11 (18 %)	49 (82 %)	60
Subdural fluids	0	2	2
	—	—	—
	11	51	62

* One patient examined before and after E.C.T.

It can be seen that 78% of the positive acetylcholine assays occurred in the traumatic groups of patients, while 65% of the negative acetylcholine assays were in the nontraumatic groups. In only two nontraumatic cases was acetylcholine found in the cerebrospinal fluid. One of these was a case of Arnold-Chiari malformation and the other a case with no central nervous system disease. With these two exceptions the nonepileptic cerebrospinal fluid samples positive for acetylcholine were restricted to cases of craniocerebral trauma (including E.C.T. cases).

Cerebrospinal fluid cholinesterase determinations were done on 111 samples from 102 patients. The results when correlated with the clinical diagnoses are summarized in Fig. 1. We have previously pointed out that there were no significant differences among the various diagnostic groups with the exception of the cases of craniocerebral trauma and those treated by E.C.T. (22). In most of the latter cases there was a tendency toward a lower rate of acetylcholine hydrolysis and a definite reversal of the usual fraction patterns, consisting of a relative decrease in the specific cholinesterase fraction (MeCh activity) and an increase in the unspecified cholinesterase fraction (BCh activity). In Table II the reversals of cholinesterase fraction patterns for the various diagnostic groups have been summarized. Of the reversals, 77% were found in the two traumatic groups of patients, whereas 91% of the cases showing no reversals were in the nontraumatic groups. Of the five nontraumatic cases with a tendency toward cholinesterase fraction reversals there were two patients with focal epilepsy and three patients with subarachnoid hemorrhage, hydrocephalus, and third ventricle tumor (with bilateral ventriculocisternostomies) respectively.

If the results of Tables I and II are compared, it is evident that patients with craniocerebral trauma showed striking differences from the rest of the patients in regard to cerebrospinal fluid analyses. These abnormalities recalled

the experimental concussion studies of Bornstein (3, 4). Accordingly detailed clinical and E.E.G. studies were combined with cerebrospinal fluid analyses in following the course of these patients.

CHARACTERIZATION of CHOLINESTERASES in HUMAN CEREBROSPINAL FLUID
AVERAGE VALUES for VARIOUS DIAGNOSTIC GROUPS

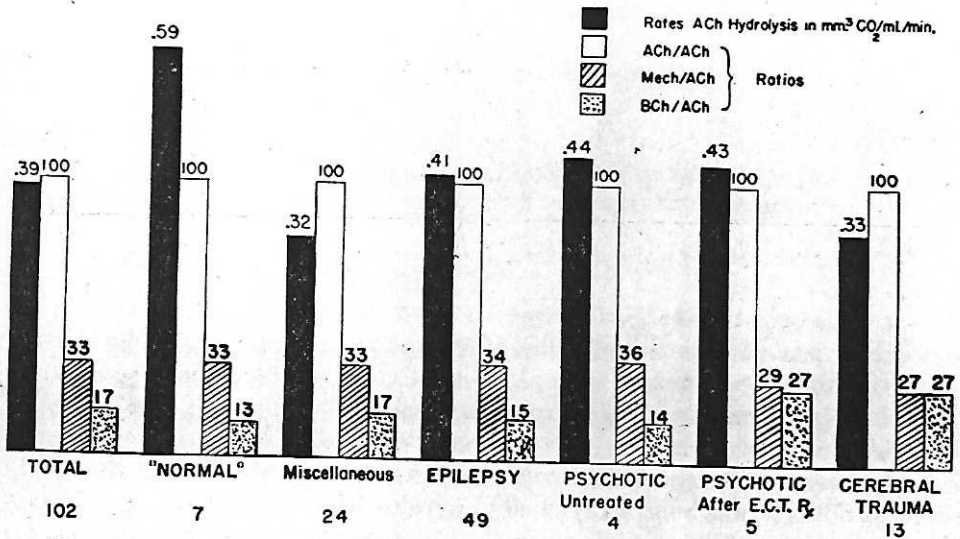


FIG. 1. Correlation of cerebrospinal fluid cholinesterase values with clinical diagnoses in 102 patients. (Diagnoses of craniocerebral trauma and psychotic cases are given in Tables III and IV respectively. Diagnoses of miscellaneous group were: intracranial tumor, five; no CNS disease, four; cerebral thrombosis, three; headache, CNS syphilis, hydrocephalus, Arnold-Chiari malformation, adhesive arachnoiditis, and aneurysm, two each; histamine cephalalgia, trigeminal neuralgia, myasthenia gravis, Menière's disease, cerebral aplasia, idiopathic increased intracranial pressure, and multiple sclerosis, one each.)

TABLE II
CEREBROSPINAL FLUID SAMPLES SHOWING REVERSAL OF NORMAL CHOLINESTERASE FRACTION PATTERNS

Sample type	Reversal	No reversal	Total
Cranio-cerebral trauma patients	12 (63 %)	7 (37 %)	19
E.C.T. treated psychiatric patients	5 (83 %)	1 (17 %)	6*
Untreated psychiatric patients	0	4 (100 %)	4*
Epileptics	2 (4 %)	47 (96 %)	49
Others	3 (9 %)	30 (91 %)	33
Total	22 (20 %)	89 (80 %)	111

* One patient examined before and after E.C.T.

2. Correlation of Cerebrospinal Fluid Analyses with Clinical and Electroencephalographic Observations

To illustrate our findings four of the cases of craniocerebral trauma are briefly summarized and discussed.

(1) Patient 911 JK, ♂, 37

Diagnosis.—Bilateral subdural hydromata, simple skull fracture of the right base and parietal bone, craniocerebral injury (Fig. 2).

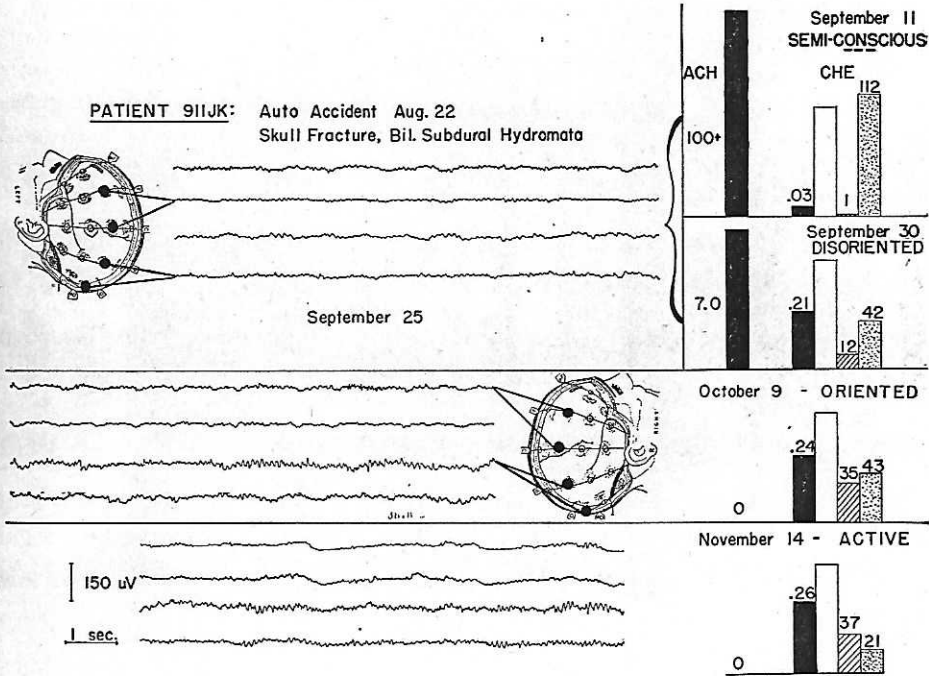


FIG. 2. Clinical, electroencephalographic, and cerebrospinal fluid acetylcholine and cholinesterase findings on Patient 911 JK. (For legend see Fig. 4).

Case abstract.—Automobile accident, Aug. 22. Rendered immediately unconscious. Admitted 24 hr. later deeply comatose with right hemiparesis, bilaterally positive Babinski signs and rectal temperature of 107° F. Comminuted fracture of right base and parietal bone demonstrated by X-ray. Bilateral subtemporal craniotomies with drainage of bilateral subdural hydromata carried out at once. Remained semicomatose for the next 20 days. Pneumoencephalogram on Sept. 11 demonstrated reaccumulation of subdural fluid. Following redrainage patient responded but was disoriented, drowsy, and at times manic and hallucinating. He became oriented on Oct. 2, and was discharged on Oct. 10. He was followed for the next year during which time he returned to active work.

The first cerebrospinal fluid sample was obtained at the time of pneumoencephalography (Sept. 11), 20 days after the accident while the patient was still semicomatose. It contained the relatively large amount of 100+ μgm. % of acetylcholine and showed a virtual absence of the specific cholinesterase fraction and a markedly reduced rate of acetylcholine hydrolysis (Figs. 2 and 3). An E.E.G. on Sept. 25 during the period of somnolence and disorientation

showed extremely low voltage records from all head leads with occasional random slow waves from the right centrotemporal region. The second cerebrospinal fluid sample, taken during the same clinical period (on Sept. 30), contained 7.0 $\mu\text{gm. } \%$ of acetylcholine and showed some improvement in cholinesterase activity with reappearance of the specific cholinesterase fraction. One week after the patient became rational an E.E.G. (Oct. 9) showed improvement with increased amplitude, return of alpha rhythm on the right and random slow waves from the left central region. A cerebrospinal fluid sample on the same day contained no acetylcholine and showed further return of the cholinesterase activity and fraction patterns toward normal. Re-examination a month after discharge (on Nov. 14) demonstrated still further improvement in the E.E.G. with return of alpha rhythm on the left and a decrease in slow wave activity. The electroencephalographic recovery was considered in general to be very good. The final cerebrospinal fluid analysis at this time showed absence of acetylcholine and a relatively normal cholinesterase fraction pattern together with further increase in cholinesterase activity (ACh hydrolysis).

The case of 911 JK presented the most marked changes of any we observed, but it is typical of the findings in all the traumatic cases studied. There were, of course, other factors in this case such as an initial pyrexia of 107° F. and operative reintervention. The justification for assuming a correlation between E.E.G. and clinical state and the cerebrospinal fluid acetylcholine and cholinesterase values rests with the other cases in our study.

(2) Patient 1118 NG, ♂, 19

Diagnosis.—Right basilar skull fracture, right epidural hematoma, cerebral contusion, craniocerebral injury (Fig. 4).

Case abstract.—Struck by hit-and-run driver on Oct. 13 and rendered momentarily unconscious. During next three hours developed headache, irritability, vomiting, and drowsiness. On examination he was found to have right basilar skull fracture by X-ray and grossly bloody cerebrospinal fluid under increased pressure. Several days later decerebrate attacks developed. Transferred to Montreal Neurological Institute on Oct. 20, where examination showed stiff neck, positive Kernig's sign, left seventh nerve paresis, paresis of left arm, and bilaterally positive Babinski signs. Ventriculogram demonstrated a fluid collection over right temporal region. Right subtemporal craniotomy and evacuation of an epidural hematoma were carried out at once. Because of his failure to respond re-explorations were carried out one and three days later, but the patient remained in a semicomatose state for the next three months. By the end of January slight improvement was evident. This became definite in the next three months. He responded to commands, walked with help, and eventually could feed himself and call for necessary articles, although he remained unable to articulate. During this period he was very restless and difficult to control. He continued to improve, regaining ability to speak, and was discharged in September.

The first cerebrospinal fluid sample was drawn about one month after admission (on Nov. 18) while the patient was still in a semicomatose state. It contained acetylcholine in a concentration of 2.0 $\mu\text{gm. } \%$ with a reduction of cholinesterase activity and a reversal of the normal fraction patterns (Fig. 4). E.E.G. at this time showed depression of cortical activity with bursts of high amplitude slow waves, particularly from the right temporo-parietal region. Three weeks later (on Dec. 9) a second cerebrospinal fluid analysis was made. It contained 1.5 $\mu\text{gm. } \%$ acetylcholine and showed a

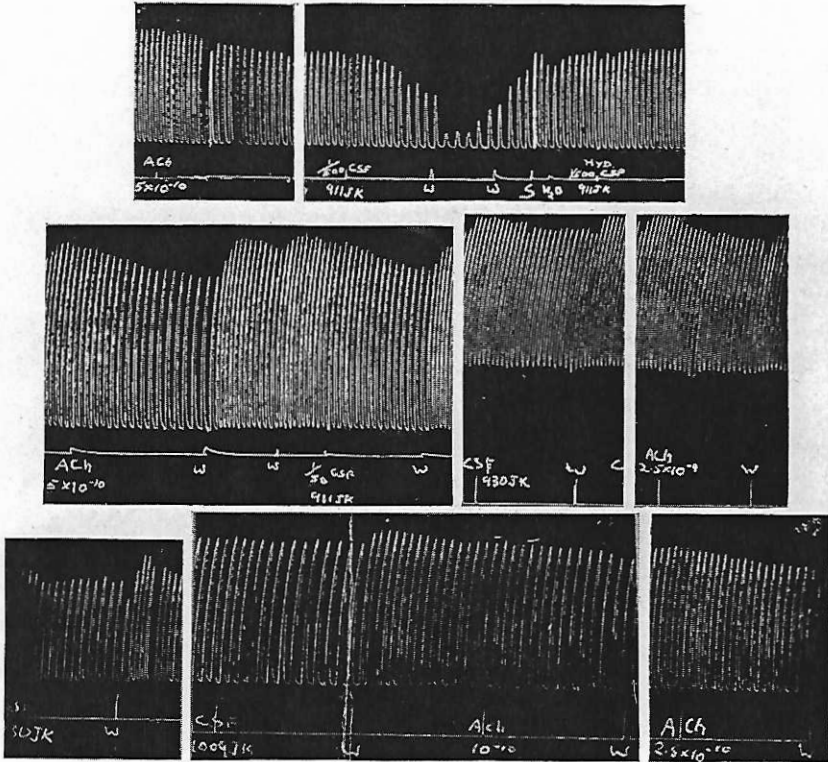


FIG. 3. Kymograph records of cerebrospinal fluid acetylcholine assays on Patient 911 JK by the Venus heart method of assay (21).

(Legend: ACh = acetylcholine (In concentrations of 2.5×10^{-9} = 10.0 $\mu\text{gm. } \%$
 5.0×10^{-10} = 2.0 $\mu\text{gm. } \%$
 2.5×10^{-10} = 1.0 $\mu\text{gm. } \%$
 10^{-10} = 0.4 $\mu\text{gm. } \%$)

w = wash

911JK = CSF sample of Sept. 11 (diluted 1 : 500 and 1 : 50 as noted)

930JK = CSF sample of Sept. 30

1009JK = CSF sample of Oct. 9)

further decrease in cholinesterase activity and more marked reversal of the fraction pattern. No change in clinical state had been observed, and an E.E.G. at this time showed some deterioration from the previous record with evidence of increasing severity of right temporoparietal damage. A third cerebrospinal fluid analysis was made three months after admission (on Jan. 22) at which time clinical improvement was beginning. In the cerebrospinal fluid 1.0 $\mu\text{gm. } \%$ of acetylcholine was still present, but cholinesterase activity and fraction patterns showed a tendency toward improvement. The E.E.G. at this time was improved with reappearance of alpha rhythm on the left and a decrease in amplitude of the slow waves. On May 10 after three months of gradual improvement a final cerebrospinal fluid analysis showed disappearance of acetylcholine and a definite return of cholinesterase values toward normal. E.E.G. at this time demonstrated continuing improvement, characterized by reappearance of alpha rhythm on the right and a disappearance of slow waves,

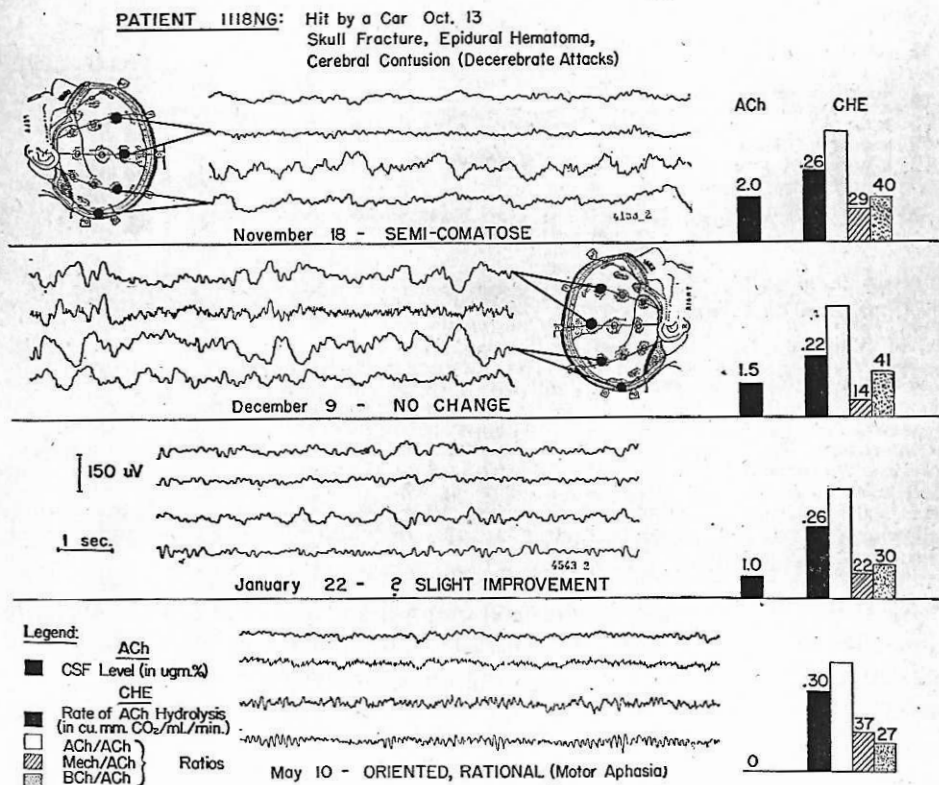


FIG. 4. Clinical, electroencephalographic, and cerebrospinal fluid acetylcholine and cholinesterase findings on Patient 1118 NG.

although some slow and sharp waves reversing over the right temporoparietal region suggested development of an epileptogenic focus there. The interesting feature of this case is the prolonged period of semicomatose without clinical or electroencephalographic improvement during which time the abnormalities in the cerebrospinal fluid acetylcholine and cholinesterase values persisted.

(3) Patient 0109 GB, ♂, 29

Diagnosis.—Left temporoparietal skull fracture, bilateral subdural hematomata, craniocerebral injury (Fig. 5).

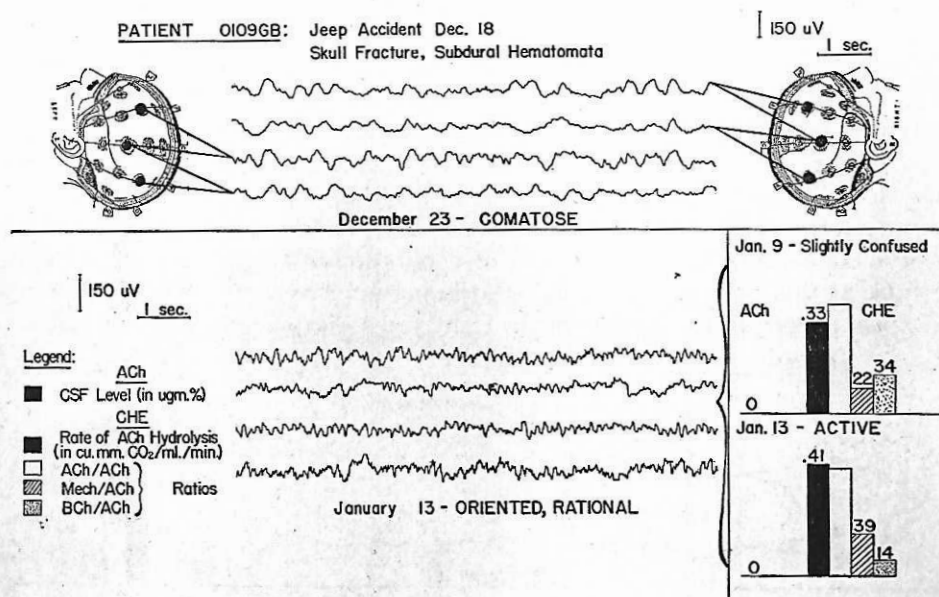


FIG. 5. Clinical, electroencephalographic, and cerebrospinal fluid acetylcholine and cholinesterase findings on Patient 0109 GB (Note: CSF analysis dated Jan. 13 should read Jan. 20).

Case abstract.—On Dec. 18 patient was thrown from jeep landing on his head. He remained in a restless, semicomatose state for five days at which time he was transferred to the Montreal Neurological Institute. On admission patient was comatose, with a left seventh nerve paresis, left hemiparesis, and left hyperreflexia. A linear left temporoparietal skull fracture was demonstrated by X-ray. Bilateral subdural hematomata were tapped by twist-drill holes immediately after admission, following which patient regained consciousness but remained confused and disoriented. Operative drainage of subdural spaces carried out the following day. Remained confused until Jan. 12 after which he was oriented and rational. Discharged on Jan. 23 well.

An E.E.G. at the time of admission on Dec. 23, when the patient was still comatose, showed evidence of generalized brain damage with absence of normal alpha rhythm (Fig. 5). During the period when the patient was confused and disoriented, the first cerebrospinal fluid sample was drawn (Jan. 9). It contained no acetylcholine but showed the typical abnormalities of cholinesterase values. An E.E.G. (Jan. 13), when the patient had become rational, showed marked improvement except for some bursts of four to six per second slow and sharp waves. A second cerebrospinal fluid sample (on Jan. 20) three days before discharge showed normal cholinesterase values. In this case the initial cerebrospinal fluid sampling was somewhat late in the post-traumatic course. Recovery had apparently progressed beyond the point where acetylcholine could still be detected in the cerebrospinal fluid, although the residual cholinesterase changes remained.

(4) Patient 0216 VB, ♂, 30

Diagnosis.—Right frontoparietal skull fracture, cerebral contusion, cranio-cerebral injury; multiple fractures right facial bones, contusion right eye (Fig. 6).

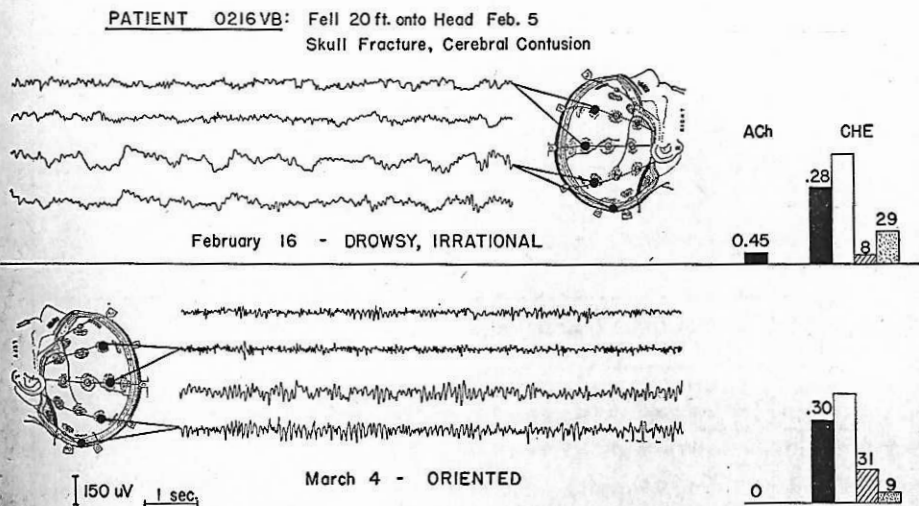


FIG. 6. Clinical, electroencephalographic, and cerebrospinal fluid acetylcholine and cholinesterase findings on Patient 0216 VB (For legend see Fig. 5).

Case abstract.—Four days before admission (Feb. 5) patient fell estimated 20 ft. onto head. Not rendered unconscious but subsequently became drowsy and irrational. On admission no neurological findings other than mental state of drowsiness and irrationality were elicited, but there was contusion of the right eye and evidence of multiple fractures of facial bones on the right. Right frontoparietal linear skull fracture demonstrated by X-ray. Pneumoencephalogram on Feb. 16 suggested possibility of space-occupying lesion on the right, but exploration of subdural and subarachnoid spaces was negative. Diagnosis of intracerebral hemorrhage was entertained. Gradual improvement took place, and he became clear and rational on Feb. 24. Discharged well on Mar. 5.

An E.E.G. on Feb. 16 showed very little rhythmic activity, high amplitude slow waves, and evidence of right frontoparietal damage (Fig. 6). Cerebrospinal fluid analysis at this time showed a small amount of acetylcholine and typical cholinesterase abnormalities. Ten days later (Mar. 4) at the time of discharge the E.E.G. was markedly improved with more regular alpha rhythm, decrease in slow wave activity, and higher amplitude of cortical activity. The cerebrospinal fluid sample taken at this time contained no acetylcholine and had normal cholinesterase values.

All 15 craniocerebral trauma cases studied are summarized in Table III. There is considerable variation from case to case, depending upon the time of sampling and the degree of trauma. As typified by the four cases cited (Figs. 2, 4, 5, 6) the essential features were the following: *first*, the presence initially of acetylcholine in the cerebrospinal fluid together with reduced activity and reversal of the normal fraction patterns of cerebrospinal fluid cholinesterases, so that the unspecified cholinesterase fraction predominated; *second*, the coinciding of these cerebrospinal fluid findings with depression of

TABLE III
CEREBROSPINAL FLUID ACETYLCHOLINE AND CHOLINESTERASE VALUES, ELECTROENCEPHALOGRAMS, AND CLINICAL STATES IN 15 CASES OF CRANIOCEREBRAL TRAUMA

Patient	Sex	Age	Diagnosis	Date	Cells per ml.		Pandy	Protein in mgm. %	ACh in μ gm. %	ChE rate**	ChE ratios		E.E.G. record	Clinical state
					RBC	WBC					MeCh/ACh	BCh/ACh		
909 JMcI	♂	32	Post-traumatic head-ache	9-9	10	2	+	35.3	0/4	0.25	43	35	Normal	Normal
911 JK	♂	37	Bilateral subdural hydromata; basal skull fracture	9-11 9-30 10-9	127 10 120	52 1 0	2+ 2+ 3+	45.1 79.5 97.2	100+ 7.0 0/0.3	0.03 0.21 0.24	1 12 35	112 42 43	{Severely depressed} Improved Good recovery	Semicoma Disoriented Oriented Active Active
919 DB	♂	14 mos.	Bilateral subdural hydromata	11-14 9-19	2 7	0 0	+	72.2 19.2	0/1 0/0.4	0.26 0.25	37 32	21 15	—	Active
922 AB	♂	29	Post-traumatic head-ache	9-22	4	2	+	24.7	0/0.3	0.27	39	19	Rhythmic instability	Active
923 GM	♀	20	Cerebral contusion	9-23	52	0	+	29.7	—	0.26	26	20	Depressed	Recovering
1118 NG	♂	20	Right epidural hematoma; right basilar skull fracture; cerebral contusion	11-18 12-9 1-22	34 93 1	8 21 0	+	37.1 57.4	2.0 1.5 1.0	0.25 0.22 0.26	29 20 22	40 41 30	Deteriorating Slight improvement	Semicoma Semicoma
1119 JS	♂	51	Right subdural hematoma	5-10 11-19	—	2	0	—	0/0.2 0/1	0.30 0.37	37 26	27 25	Marked recovery Improved	Oriented Recovering
1120 AF	♂	24	Right temporal skull fracture	11-20	20	0	—	18.7	0/1	0.41	27	19	—	Recovering
0109 GB	♂	29	Left temporoparietal skull fracture; bilateral subdural hematoma	1-9 1-20	9 163	10 77	±	31.6 30.5	0/0.3 0/1	0.33 0.41	22 39	34 14	{Much improved}	Confused Recovering
0109 ILAP 0110 AF	♂ ♂	18 58	Cerebral contusion Right temporoparietal skull fracture; right epidural hematoma; cerebral contusion	1-9 1-10	14 15	0	±	49.1 32.5	0/0.3 0/0.3	0.64 0.34	34 39	22 46	Normal	Active Semicoma
0216 VB	♂	30	Right frontoparietal skull fracture; cerebral contusion	2-16 3-4	—	36	+	44.3 61.0	0.45 0/0.1	0.28 0.30	8 31	29 9	Depressed Much improved	Drowsy Oriented
0226 ED	♂	42	Left parieto-occipital multiple compound depressed skull fractures; left epidural hematoma; cerebral contusion	2-26	—	—	2+	97.2	0.2	0.60	20	27	Low amplitude	Manic
V1205 KJ***	♂	3 mos.	Hydrocephalus, communicating, post-traumatic	12-5	—	—	4+	527	0	2.93	4	50	—	—
0203 CE*** 911 JK***	♂ ♂	45 37	Cranio-cerebral injury (See above)	2-3 9-11	—	—	4+ 4+	1106 180	0 0	1.05 2.23	10 18	50 47	—	—

* Acetylcholine levels that are negative are expressed as 0/threshold of test object in μ gm. %.
** Cholinesterase rate in cu. mm. CO₂/ml. CSF/min.
*** Subdural fluid samples.

the E.E.G. and the clinical state; *third*, parallel improvement of E.E.G. and clinical state with disappearance of acetylcholine from the cerebrospinal fluid and return toward normal of cerebrospinal fluid cholinesterase values (the cholinesterases apparently being more sensitive indicators in this regard); and *fourth*, an apparent rough correlation of acetylcholine levels in the cerebrospinal fluid with the extent of clinical and E.E.G. abnormalities, so that with high acetylcholine levels depression was observed, while at low acetylcholine levels excitatory phenomena occurred. The observations correspond in general to the more precise experimental studies of Bornstein (3). In some cases other factors, in particular operative intervention, must be taken into account. Contamination of cerebrospinal fluids with subdural fluid, as seen in the last two cases of Table III (*V1205 KJ* and *0203 CB*), can be readily differentiated (22). In our other reports, factors of age, sex, cerebrospinal fluid cellular reaction, cerebrospinal fluid protein level, and medication of the patients have been shown to be of little or no significance for the results of cerebrospinal fluid acetylcholine and cholinesterase determinations. With the exception of cases of epilepsy and craniocerebral trauma clinical diagnoses have not had any bearing on results. The finding of acetylcholine in the cerebrospinal fluid in the presence of considerable amounts of cholinesterases has been shown to be possible because of the minimal or absent cholinesterase activity at such suboptimal substrate concentrations (8, 22, 23).

3. Cerebrospinal Fluid Acetylcholine and Cholinesterase Studies in Nine Psychiatric Patients

In the nine psychiatric patients available for study only cerebrospinal fluid acetylcholine and cholinesterase determinations were possible. Four of these patients received no E.C.T. treatments prior to sampling. One of these (patient *0121 EF*) was resampled after five E.C.T. treatments. The other five patients were sampled only after several E.C.T. treatments had been given.* The diagnosis and results of cerebrospinal fluid studies on these patients are summarized in Table IV.

Cerebrospinal fluid samples from the four untreated patients contained no acetylcholine and had normal cholinesterase values. In contrast the E.C.T. treated patients, with a single exception (patient *0120 HO'R*), all showed changes in cerebrospinal fluid cholinesterase fraction patterns similar to those previously described for cases of craniocerebral trauma, namely, an increase in the unspecified cholinesterase fraction (BCh activity) and a decrease in the specific cholinesterase fraction (MeCh activity). In only two of the E.C.T. treated patients was acetylcholine found in the cerebrospinal fluid samples. Patient *0121 EF* is most interesting because pre- and post-treatment samples

* All electric shock convulsant therapy (E.C.T.) was given at the Allan Memorial Institute of the Royal Victoria Hospital. The patients were routinely pretreated to drowsiness with intravenous sodium amytal. Electric shocks were administered from a standard Offner or Rahm machine through two electrodes, placed on vertex and temple respectively. In all these cases a convulsant dose of 700 ma. at a pulse interval of 0.7 msec. was applied for a treatment duration of two seconds.

TABLE IV

CEREBROSPINAL FLUID ACETYLCHOLINE AND CHOLINESTERASE VALUES IN NINE PSYCHIATRIC PATIENTS

Patient	Sex	Age	Diagnosis	No. of E.C.T.	ACh in $\mu\text{gm.}\%$ *	ChE Rate**	ChE ratios	
							MeCh/ACh	BCh/ACh
1209 TD	♂	19	Anxiety state	0	0/1	0.42	36	12
1230 EM	♂	37	Infectious psychosis	0	0/0.02	0.42	37	9
0128 AG	♀	43	Anxiety state	0	0/0.3	0.60	34	18
0121 EF	♀	48	Manic-depressive	0	0/0.1	0.32	36	16
				5	0.2	0.32	29	30
0119 RS	♀	37	Manic-depressive	6	1.0	0.59	18	32
0119 DM	♀	37	Reactive depression	6	0/1	0.25	28	30
0120 HO'R	♀	56	Involutional melancholia	7	0/1	0.62	35	18
0120 IG	♀	32	Reactive depression	3	0/1	0.48	33	29
0130 EC	♀	36	Manic-depressive	3	0/1	0.30	36	30

* *Acetylcholine levels that are negative are expressed as 0/threshold of test object in $\mu\text{gm.}\%$.*

** *Cholinesterase rate in cu.mm. $\text{CO}_2/\text{ml. CSF}/\text{min.}$*

were obtained. The appearance of acetylcholine in the cerebrospinal fluid and the reversal of cholinesterase fraction patterns after five E.C.T. treatments were quite striking in this patient.

The number of cases and the number of samples on each case are small but some conclusions seem warranted. The most marked cerebrospinal fluid abnormalities seemed to occur in cases with the most E.C.T. treatments. Because of the small quantities of acetylcholine found it is possible that some low acetylcholine values were missed. No explanation for the exception of patient 0120 HO'R to the general trend of cholinesterase values in the other five patients could be found. It is interesting that this patient was the only one of the six to show no response to treatment.

Because of the findings presented in Table IV, together with the findings in accidental craniocerebral trauma (Table III) and cases of spontaneous epileptic seizures (22), we regard the cerebrospinal fluid abnormalities in E.C.T. treated cases as due to a kind of cerebral trauma produced by the electric shock. The less marked cerebrospinal fluid abnormalities in E.C.T. cases would be consistent with the milder degree of trauma delivered. In dogs given convulsant doses of electric shock Bornstein (4) found acetylcholine in the cerebrospinal fluids of several animals. Bornstein and Stern (5), Brecht and Kummer (6), and Himwich (11) have reported finding acetylcholine in the cerebrospinal fluids of patients following electric shock therapy. None have reported on the cerebrospinal fluid cholinesterases. Abnormalities in the E.E.G. (slow wave activity) (13) and atrophic gyri beneath the sites of electrode application (19) have been found after repeated E.C.T. treatments. These observations support our findings in the nine psychiatric patients studied.

Discussion

The study of patients is beset with difficulties that can often be circumvented in animal experiments. Bornstein (3) observed during perfusion of the cortex of the unanesthetized dog and cat a correlation between acetylcholine levels in the cerebrospinal fluid and the E.E.G. pattern and behavior of the animals. We have observed this in the human cases reported here. With high acetylcholine levels (over 1.0 to 2.0 $\mu\text{gm. } \%$) disturbances of consciousness up to semicoma or coma together with depression of electroencephalographic activity were seen by both Bornstein (3) and us. As the level of acetylcholine decreases, patients and animals went through a period of restlessness and confusion before becoming normal. This was associated with increased activity (particularly slow and sharp waves) in the E.E.G. The cerebrospinal fluid cholinesterase changes, observed in our patients, seem to be even more sensitive indicators of the post-traumatic state than either the cerebrospinal fluid acetylcholine level or the E.E.G. The persistence of cholinesterase changes for long periods of time and their reversion to normal values coincident with clinical improvement are significant.

It is not clear what the mechanisms are for the findings reported here. Acetylcholine may be liberated because of trauma to cerebral tissue (15) or during mass neuronal discharges following trauma (25) or both. Bornstein (3) has shown that acetylcholine in the concentrations found can produce the observed effects on the E.E.G. and clinical state. In our study of epileptic patients 77% had cerebrospinal fluid samples positive for acetylcholine in concentrations lower than those seen in traumatic cases (8, 23). It has been suggested that the liberation of acetylcholine into these cerebrospinal fluids was due to the repeated trauma to the cortex of epileptic seizures. If this were so, changes in cerebrospinal fluid cholinesterases might also be expected to be present. This is not the case (22), which suggests that the appearance of acetylcholine in cerebrospinal fluids of epileptics involves a different mechanism from that seen in craniocerebral trauma.

Where the cerebrospinal fluid cholinesterase abnormalities also fit into the picture is difficult to say. We have previously suggested that the specific cholinesterase fraction is derived from nervous tissue and that the unspecified fraction is contributed by an extra-neural source (22). The increased permeability of the blood-brain barrier following trauma could account for the increase in unspecified cholinesterase. The report of Kabat *et al.* (14) is in accord with this idea. Since Cohn *et al.* (7) have shown unspecified cholinesterase to be carried in the α_2 globulin plasma protein fraction, it should be possible to apply the methods of Kabat *et al.* (14) to the further elucidation of this problem. The changes in the specific cholinesterase fraction may be due to relative inactivation of this enzyme fraction by increased destruction, decreased production, temporary inhibition, dilution with anenzymatic fluid, or any combinations thereof. It is conceivable that in certain cases craniocerebral trauma might impair the capacity of specific cholinesterase in cerebral

tissue to cope with the high concentrations of acetylcholine liberated, so that the clinical course of the patient could be considerably altered (22). We feel that changes in the cerebrospinal fluid reflect changes in cerebral tissues and that attention should now be directed to an investigation of these tissues.

Further studies of the problem may result in new treatments of the post-traumatic patient. The use of atropine to counteract the effects on the E.E.G. and clinical state of abnormally high cerebrospinal fluid concentrations of acetylcholine has been suggested by Bornstein (3). Darrow *et al.* (9), Grob *et al.* (10), and Wescoe *et al.* (26) have reported studies consistent with this idea. It is also of interest that Mendel and Hawkins (16) and Hyde *et al.* (12) have used cholinesterase experimentally to alter neuronal activity. Red blood cells, rich in specific cholinesterase, are still a relatively unused by-product of plasma production, which could be made available for trial in craniocerebral trauma. We have not yet had sufficient opportunity to investigate these and other promising therapeutic approaches. The possibilities for furthering our understanding of the pathological neurophysiological processes in craniocerebral trauma and of the biochemistry of neuronal activity are many.*

Acknowledgments

We wish to express our appreciation to Drs. William V. Cone and Arthur R. Elvidge for the opportunity to study the cases of craniocerebral trauma and to Dr. Ewen Cameron, director of the Allan Memorial Institute, for the opportunity to study the psychiatric cases.

References

1. (a) AMMON, R. Arch. ges. Physiol. (Pflügers), 233 : 486. 1933.
- (b) AUGUSTINSSON; K-B. Acta Physiol. Scand. 15 (Suppl. 52) : 1. 1948.
2. BABKIN, B. P., SCHACHTER, M., DWORKIN, S., and ROSENBERG, G. M. Rev. can. biol. 1 : 761. 1942.
3. BORNSTEIN, M. B. J. Neurophysiol. 9 : 349. 1946.
4. BORNSTEIN, M. B. Unpublished data. 1948.
5. BORNSTEIN, M. B. and STERN, K. Unpublished data. 1948.
6. BRECHT, K. and KUMMER, H. Klin. Wochschr. 22 : 741. 1943.
7. COHN, E. J., STRONG, L. E., HUGHES, W. L., MULFORD, D. L., ASHWORTH, J. M., MELIN, M., and TAYLOR, H. L. J. Am. Chem. Soc. 68 : 459. 1946.
8. CONE, W. V., TOWER, D. B., and McEACHERN, D. Trans. Am. Neurol. Assoc. 73 : 59. 1948.
9. DARROW, C. W., PATHMAN, J. H., and KRONENBERG, G. Federation Proc. 4 : 16. 1945.
10. GROB, D., HARVEY, A. M., LANGWORTHY, O. R., and LILIENTHAL, J. A. Bull. Johns Hopkins Hosp. 81 : 257. 1947.
11. HIMWICH, H. E. J. Am. Med. Assoc. 136 : 870. 1948.
12. HYDE, J. E., BECKETT, S., and GELHORN, E. Federation Proc. 6 : 133. 1946.
13. JASPER, H. H. Personal communication. 1948.
14. KABAT, E. A., GLUSSMAN, M., and KNAUB, V. Am. J. Med. 4 : 653. 1948.
15. LORENTE DE NÓ, R. Am. J. Physiol. 121 : 331. 1938.

* Since completion of this paper the extensive review on cholinesterases by Augustinsson (1b) has appeared. It contains many results and ideas germane to the present study.

16. MENDEL, B. and HAWKINS, R. D. *J. Neurophysiol.* 6 : 431. 1943.
17. NACHMANSOHN, D. and ROTHENBERG, M. A. *J. Biol. Chem.* 158 : 653. 1945.
18. ODOM, G., RUSSEL, C. K., and McEACHERN, D. *Brain*, 66 : 1. 1943.
19. PENFIELD, W. Personal communication. 1948.
20. TOWER, D. B. *Can. J. Research, E*, 27 : 20. 1949.
21. TOWER, D. B. and McEACHERN, D. *Can. J. Research, E*, 26 : 183. 1948.
22. TOWER, D. B. and McEACHERN, D. *Can. J. Research, E*, 27 : 132. 1949.
23. TOWER, D. B. and McEACHERN, D. *Can. J. Research, E*, 27 : 120. 1949.
24. WAIT, R. B. *Biol. Bull.* 85 : 79. 1943.
25. WALKER, A. E., KOLLROSS, J. J., and CASE, J. J. *J. Neurosurg.* 1 : 103. 1944.
26. WESCOE, W. C., GREEN, R. E., McNAMARA, B. P., and KROP, S. *J. Pharmacol. Exptl. Therap.* 92 : 63. 1948.